



University of Wisconsin
**SCHOOL OF MEDICINE
AND PUBLIC HEALTH**

Fundus Photograph Reading Center

Modified 3-Standard Field Digital Color Fundus Photography (3M-D)

Effective Date: *22 Jun 2012*

Table of Contents

1. 3M-D Overview	2
2. Photographer Certification	2
2.1. Overview	2
2.2. Certification Requirements.....	2
2.2.1. Images Required if Previously Certified.....	2
2.2.2. Images Required if Not Previously Certified.....	3
2.3. Submission for Certification	3
2.4. Uncertified Photographers.....	3
2.4.1. Baseline/Screening Visits.....	3
2.4.2. Follow-up Visits.....	3
3. Fundus Cameras	3
4. Modified 3-Standard Stereoscopic Fields and Fundus Reflex Images.....	3
5. Submitting Study Images to the FPRC.....	5
6. Evaluation of Image Quality	5
6.1. At the Study Site.....	5
6.2. At the FPRC	5
7. Pointers on Imaging Technique.....	6
7.1. General	6
7.2. Patient Cooperation	6
7.3. Photo Sequence	6
7.4. Focus/Clarity	6
7.5. Stereoscopic Effect.....	7
7.6. Exposure, Gain, and Flash.....	7
8. References	8

1. 3M-D Overview

This document details the Fundus Photograph Reading Center (FPRC) procedure for photographer certification, provides instruction to image the Modified 3 Standard Fields (3M-D) and lists pointers on imaging technique.

This document also provides information and references for digital system certification. Digital systems must be certified for each study separately. See the *Digital System Certification* document for further details.

Further clarification regarding any information included in this document may be obtained by contacting the FPRC Imaging staff at (608) 410-0619 or by sending an email to Imaging_administrators@rc.ophth.wisc.edu.

2. Photographer Certification

2.1. Overview

Photographer certification is specific to each study and photographers taking digital images for studies evaluated by the FPRC must be certified for the relevant procedure(s), before submitting actual subject images. The certification images may be taken on subjects being photographed for clinical purposes or of volunteers. Once a photographer is certified for a specific study, he/she is certified for the duration of that study, provided he/she meets the quality standards set by the FPRC. See section 6 *Evaluation of Image Quality*.

2.2. Certification Requirements

Certification consists of:

- Review of the study synopsis/protocol and imaging procedure(s)
- The ability to perform the imaging procedure(s), demonstrated by the submission of images of acceptable quality.

2.2.1. Images Required if Previously Certified

The second certification requirement listed above will be waived if all of the following criteria are met:

- The photographer has prior certification at the FPRC using **an identical procedure**.
- The photographer has been actively taking images during the past 12 months.
- The images are judged to be of good quality by the FPRC.

If a photographer thinks that these criteria have been met, or that he/she has been certified by the FPRC for a similar procedure, submit a certification request (see section 2.3 *Submission for Certification*) without sending images.

2.2.2. Images Required if Not Previously Certified

Submit a certification request (see section 2.3 *Submission for Certification*) and send color images of four eyes (two right eyes and two left eyes) taken using this procedure (3M-D).

2.3. Submission for Certification

Photographers are encouraged to send complete submissions for each procedure for which they are requesting certification (i.e., if four eyes are required for a certification submission, send all four eyes together).

Photographers who meet certification criteria will receive confirmation of certification. Those who do not meet these criteria will receive feedback from the FPRC Imaging consultants and may be required to submit additional sets of images. A plan for improving image quality may be necessary after three complete unsuccessful certification submissions.

2.4. Uncertified Photographers

2.4.1. Baseline/Screening Visits

Only FPRC-certified photographers are allowed to take baseline (screening visit) photos, unless an exception to this rule is granted (on a case-by-case basis) by the study sponsor. The baseline images for a subject are critical since all follow-up measurements are compared to this point to determine the study outcome.

The sponsor may suspend subject enrollment if the site does not have a certified photographer available to take the baseline images.

2.4.2. Follow-up Visits

On rare occasions during **follow-up** visits ONLY, when a certified photographer is not available, an uncertified photographer familiar with the procedure(s) may take the images. The uncertified photographer should review the imaging procedure(s) before performing photography to be certain he/she understands the procedure and follows the study requirements. Include a comment with the submission or any official documentation indicating that the images were taken by an uncertified photographer and the reason why..

3. Fundus Cameras

Retinal cameras suitable for this procedure will have 30° or 35° magnification settings. Canon retinal camera models used at the 40° setting are also suitable. Cameras without an optical 30° or 35° magnification setting may be suitable but will be evaluated on a case-by-case basis. Contact the FPRC if you have questions about the camera you intend to use.

4. Modified 3-Standard Stereoscopic Fields and Fundus Reflex Images

The modified 3-standard stereoscopic fields for color photography specified by this procedure differs from the ETDRS 7-standard field protocol in the position of two fields: Field 1M and

Field 3M are both modified to include the center of the macula, in Field 1M near the edge of the field and in Field 3M midway between the edge and center of the field.

The following descriptions of the standard fields assume that there are two cross hairs in the camera ocular, one vertical and the other horizontal, intersecting in the center of the ocular.

Field 1M- Optic Disc: Center the temporal edge of the optic disc at the intersection of the cross hairs. The optic disc will be off center, providing a partial view of the macula.

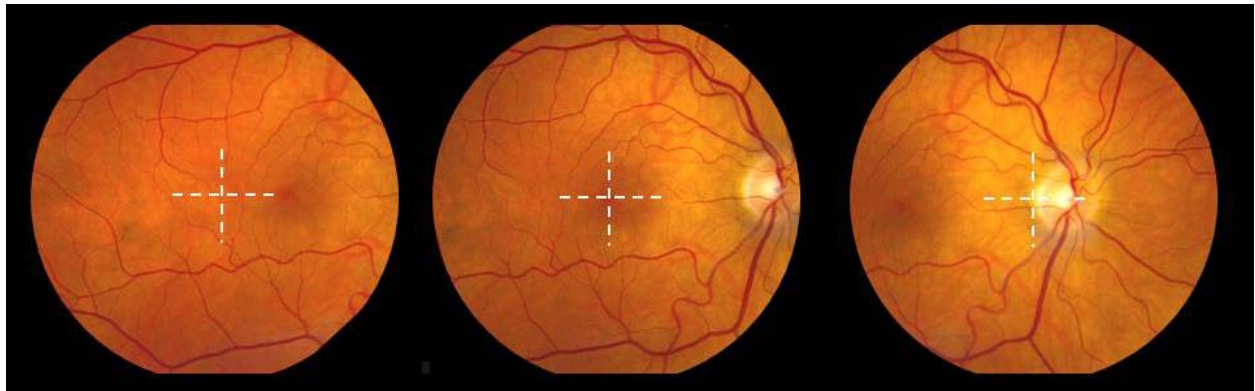
TIP: *When the optic disc is not centered in Field 1M, the center of the macula can be seen off to the side.*

Field 2-Macula: Center the macula near the intersection of the cross hairs in the ocular. A suitable position can often be obtained by rotating the camera temporally from the Field 1M position, without vertical adjustment being necessary.

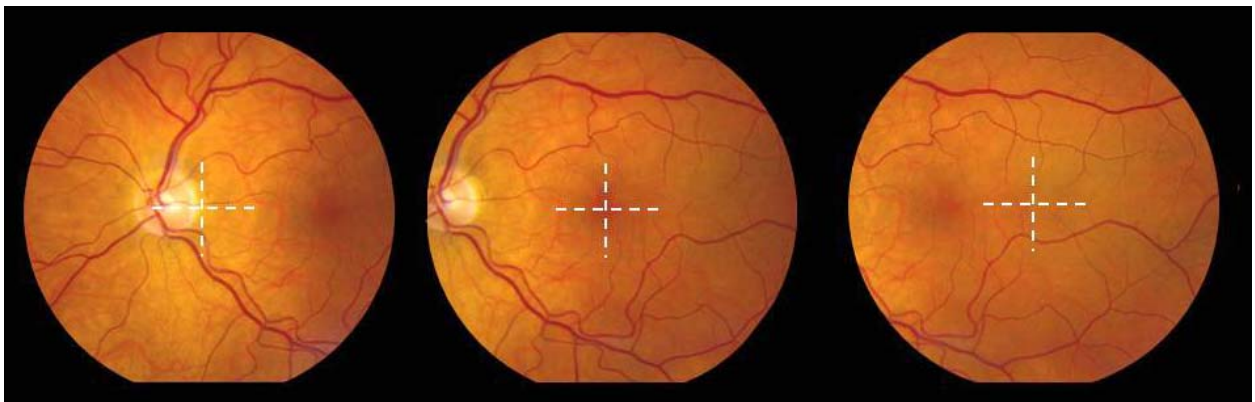
Field 3M-Temporal to Macula: Position the intersection of the cross hairs in the ocular 1.0-1.5DD temporal to the center of the macula. In this position, the macula will appear mid-way between the edge and the center of the monitor view.

TIP: *This position is easily achieved by rotating the camera temporally from Field 2 without making any vertical adjustment or movement of the fixation device.*

Fields 1M, 2, and 3M of the right and left eyes are illustrated in the figures that follow.

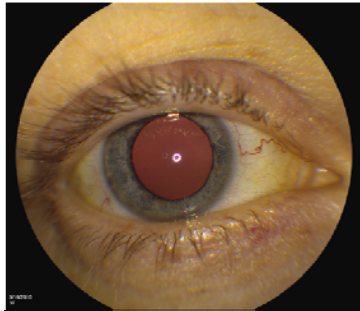


Right eye of the 3-modified fields



Left eye of the 3-modified fields

At all visits, stereoscopic fundus reflex images (an external eye view) should be taken to document media opacities. If no opacities are present, focus on the pupillary margin of the iris. If opacities are present, focus on the lens opacities. The magnification of these images should match that of the image in the figure below. The best stereo effect is obtained by moving the camera laterally about 3mm between exposures. The lateral shift can be obtained by moving the joystick. A fixation target should be positioned to direct the subject's gaze in the primary (straight ahead) position, so the optic disc *does not appear* directly behind the lens.



Fundus Reflex

5. Submitting Study Images to the FPRC

Images should be saved using no compression or lossless compression (PNG). For additional information on specific image handling procedures, see the *Digital System Certification* document.

6. Evaluation of Image Quality

6.1. At the Study Site

The color images should be evaluated for quality by the principal investigator and/or photographer (unless prohibited by Study Protocol) before submission to the FPRC. If quality is not adequate for assessment of key features of the study eye (such as extent of macular edema), and if no irremediable cause of inadequate quality is present (such as lens opacities or a pupil that will not dilate adequately), the images should be retaken before submission to the FPRC.

6.2. At the FPRC

Color images of each eye are reviewed and assigned a grade for overall quality. Feedback will be provided to the photographers as needed to help with resolution of any problems. Special attention will be given to photographers having difficulty meeting study photo quality standards. If a certified photographer consistently fails to meet study standards, certification may be suspended.

7. Pointers on Imaging Technique

7.1. General

When shooting the fields, shoot the study eye images first, followed by the fellow eye. Stereo pairs should be taken consistently, usually shooting the left member of the pair first, followed by the right member of the pair. All images should be reviewed for quality at the time of photography, and the photographer should select the best stereo pairs for each field, deleting extra images.

7.2. Patient Cooperation

Photography of the photophobic subject can be challenging for the photographer and uncomfortable for the subject. Minimizing the number of flashes and the length of time the eye is exposed to a bright viewing lamp are two things that can help make the photography procedure more comfortable. Additionally, keeping the view lamp as low as possible (maybe even dimming the room lights) can help make the photography procedure more tolerable. Patients should be asked to blink frequently to help keep the cornea clear.

If the subject has difficulty tolerating the screening visit photography procedure and the photographer thinks this will lead to a problem at follow-up visits, the situation should be discussed with the principal investigator and/or coordinator. In such cases, consideration should be given to not enrolling the subject in the study.

7.3. Photo Sequence

When the modified 3-standard stereo fields are taken, the following sequence is recommended: optic disc (Field 1M), macula (Field 2), and temporal to macula (Field 3M). Stereo Fields 1M, 2 and 3M may be taken on the same horizontal plane. Fundus reflex image(s) should be taken of all eye(s) imaged, either before or after the retinal photos.

7.4. Focus/Clarity

The best image quality is obtained if corneas are not disturbed by prior examination with a diagnostic contact lens.

In a properly aligned digital system, the cross hairs and the retina are in focus at the same time. In these instances, constant attention must be paid to keeping the cross hairs in the camera ocular in focus when focusing on the retinal vessels. However, some digital systems are not parfocal with the eyepiece; in these cases, it is important to confirm that the image on the monitor is as sharp as possible. Proper camera-to-eye distance should be maintained to avoid haziness and artifacts.

If it is not possible to get the entire photographic field in crisp focus, the photographer should concentrate on getting the center of the field in focus, sacrificing a bit on the periphery if necessary. The photographer may need to re-focus when moving from Field 1M to Field 2.

A common problem is focusing below the surface of the retina. Images that include the optic nerve (Fields 1M and often Field 2) sometimes show clear focus on the bottom of the optic cup, while the retinal surface is slightly out of focus. Primary focus should be on fine retinal

vessels near the fovea. It may help to err on the side of focusing slightly above the retina rather than too deep. This should keep both the anterior surface of the retina and the pigment epithelial background in focus. Such a strategy is more important when macular edema is present.

7.5. Stereoscopic Effect

Dilation of the pupil to at least 6mm is important to permit good quality stereo photography. If the pupils cannot be dilated to at least 4mm for the screening visit, the stereo effect will be minimal or nonexistent.

The technique described by Allen¹ is used for taking non-simultaneous stereo fundus images. The camera **should not be rotated or pivoted between members of the stereo pair**; instead, it should be moved laterally from left to right with the joystick (or by sliding the camera base on its table, if preferred). Try to obtain about 2mm as the minimum separation between members of the stereo pair when moving the joystick or sliding the camera.

Stereo pairs should be taken shooting the left member of the pair first, followed by the right member of the pair. When obtaining stereo pairs, care should be taken that at least one member of the pair is of good technical quality with crisp focus. In many cases, it will be possible to obtain good quality in both members of the pair, but if this is not the case, the aim should be to obtain good quality in one member and some stereo separation between the members, accepting somewhat poorer quality in the second member of the pair, if necessary. A video tutorial on stereo technique can be accessed on the FPRC web site at:

<http://eyephoto.opth.wisc.edu/Videos.html>.

7.6. Exposure, Gain, and Flash

It is important that photographers adjust flash, gain, and gamma to obtain optimal exposure, as well as avoiding severe over or under exposure. Over exposure is more damaging than under exposure often resulting in total loss of image detail. We recommend that photographers become familiar with using the camera and software controls available to ensure optimal exposure and good color balance. The most commonly occurring color balance problem we see is an over saturation of the red channel. The FPRC Imaging staff is available to assist in recommending acceptable settings.

Most digital systems have a wide variety of image enhancement tools to adjust image contrast, brightness or sharpness after image capture. Enhancement tools should not be used at the clinical site to adjust image quality. Pay careful attention to obtaining optimum exposure and image sharpness so that enhancements are not necessary. For more information on color balance for retinal images, read the Color Balance Paper on our website by clicking on the hyperlink [Color Balance of Film Vs. Digital Retinal Images](#) or by going to the Digital System Certification section of the website (<http://eyephoto.opth.wisc.edu/DSES.html>).

¹ Allen L. Ocular fundus photography. *Am J Ophthalmol* 1964; 57:13-28.

8. References

Early Treatment Diabetic Retinopathy Study Research Group, Manual of Operations. Chapter 13. Baltimore: ETDRS Coordinating Center, University of Maryland. Available from: National Technical Information Service, 52285 Port Royal Road, Springfield, VA 22161; Accession No. PB85 223006/AS Chapter 13.

Macular Photocoagulation Study Group, Macular Photocoagulation Study: Manual of Procedures. MPS Coordinating Center, Baltimore, MD. Available from National Technical Information Service, 5285 Port Royal Road, Springfield, VA 22161; Accession No. PB90-207903.

Age Related Eye Diseases Research Group, Manual of Operations. Chapter 8. Potomac, MD: AREDS Coordinating Center, EMMES Corporation, 11325 Seven Locks Road, Suite 214, Potomac, MD 20854.